Ultrasound Obstet Gynecol 2011; **37**: 179–183
Published online 7 December 2010 in Wiley Online Library (wileyonlinelibrary.com). **DOI:** 10.1002/uog.7684

Hepatic venous Doppler in the evaluation of fetal extrasystoles

Y. SAEMUNDSSON, C. JOHANSSON, S. WENLING and S. GUDMUNDSSON

Lund University, Department of Obstetrics and Gynecology, Malmö University Hospital, Malmö, Sweden

KEYWORDS: arrhythmia; congenital heart malformation; Doppler; echocardiography; extrasystole; fetus; hepatic veins; ultrasound

ABSTRACT

Objectives *To evaluate the use of fetal hepatic venous Doppler in the diagnosis of fetal extrasystoles, to estimate the prevalence and persistence of extra atrial and ventricular heart beats throughout pregnancy, labor and delivery, and to estimate the frequency of coexisting congenital heart disease.*

Methods *This was a retrospective study of 256 singleton pregnancies attending our hospital as outpatients due to fetal extrasystoles. Hepatic venous Doppler and detailed fetal echocardiography were performed. Information on fetal heart rate patterns during labor and neonatal conditions was collected. Congenital heart malformations and the frequency and persistence of fetal extrasystoles were noted.*

Results *On venous Doppler examination, 228 (89%) of the fetuses showed signs of supraventricular extrasystoles (SVES) and 28 (11%) had ventricular extrasystoles (VES). One fetus with SVES developed atrial flutter during pregnancy and another case developed supraventricular tachycardia postnatally. SVES persisted until labor and delivery in 28 (12.3%) fetuses and VES persisted in six (21.4%). In 31 of 34 (91.2%) fetuses with extrasystoles during labor and delivery, the conduction pattern normalized within 3 days. Five neonates were referred for evaluation by a pediatric cardiologist. Two cases had congenital heart disease. Extrasystoles persisted until labor and delivery more frequently in male fetuses* ($P < 0.0001$).

Conclusion *Hepatic venous Doppler can differentiate between SVES and VES. Despite being the more uncommon of the two, VES persists throughout pregnancy more often. Our results strongly support the suggestion that extrasystoles are a benign finding, with very few cases developing tachycardia or having a coexisting congenital heart malformation.*

INTRODUCTION

Fetal arrhythmias occur in 1–2% of all pregnancies[1,2]. Of these, approximately 90% are extrasystoles, of atrial, junctional or ventricular origin[3]. Extrasystoles are considered to be benign in character, though in a small number of cases they coexist with congenital heart defects and in about 1% of cases they lead to life-threatening tachyarrhythmias[4–6].

Concerned parents of affected fetuses demand information and management, and reliable methods for evaluation and surveillance are important. Fetal echocardiography is traditionally performed in order to detect and classify potentially harmful electrical conductions and congenital anomalies. Methods such as two- and three-dimensional ultrasound imaging as well as M-mode and pulse-wave echocardiography are frequently used during fetal evaluation. Using M-mode, the movement of atrial and ventricular walls can be assessed, and differences in rate and conduction of signals between atria and ventricles can thus be evaluated. Pulse-wave echocardiography, by placing the sample volume in the left ventricle, can record blood flow in and out of the left ventricle simultaneously, which can also provide information about conduction between the atrium and ventricle.

Blood flow in the fetal central veins pulsates as a reflection of pressure within the right atrium. Typical blood flow velocity patterns have been described in different arrhythmic conditions[7]. Fetal venous Doppler can differentiate extrasystoles that are atrial from those that are ventricular in origin, but it cannot differentiate

Correspondence to: Prof. S. Gudmundsson, Lund University, Department of Obstetrics and Gynecology, Malmö University Hospital, S - 205 02 Malmö, Sweden (e-mail: saemundur.gudmundsson@med.lu.se)

Accepted: 29 April 2010

those with junctional from those with ventricular origin. This new technique has great potential, but has not yet been evaluated clinically in the fetal setting.

The aim of this study was to assess the usefulness of fetal hepatic venous Doppler in the evaluation and diagnosis of premature fetal heart contractions. The prevalence of atrial and ventricular events and persistence of these throughout pregnancy, labor and delivery were estimated, as was the frequency of coexisting congenital heart malformations.

METHODS

This was a retrospective study of 268 singleton pregnancies referred over an 8-year period for evaluation of fetal arrhythmia detected during fetal auscultation, as part of routine antenatal maternity care, or ultrasound fetometry. The information was obtained from hospital computer files. Excluded from analysis were nine fetuses with bradycardia, one with atrial flutter and two with supraventricular tachycardia. The remaining 256 cases had an irregular heart rhythm. The median gestational age at diagnosis was 34 (range, 18–41) weeks. Figure 1 illustrates the gestational age distribution at detection; arrhythmia was detected at routine 18–20-week ultrasound screening in only four cases, while there was a peak at routine 32–34-week ultrasound screening. Immediately following detection, a Doppler evaluation was performed by a trained ultrasonographer.

Doppler was performed using an Acuson Sequoia 512 (Siemens, Mountain View, CA, USA) or a GE Voluson 730 (GE Healthcare Technologies, Milwaukee, WI, USA) ultrasound machine with color and pulsed-wave Doppler options. The umbilical artery was recorded in a free floating central part of the cord. The blood velocity spectrum was analyzed for pulsatility index (PI) according to Gosling *et al.*[8] and related to normal reference values[9].

Using ultrasound imaging, the fetal liver was then located in a transverse oblique scan of the fetal abdomen and the hepatic veins were visualized by color Doppler as they spread out from the inferior vena cava (IVC)

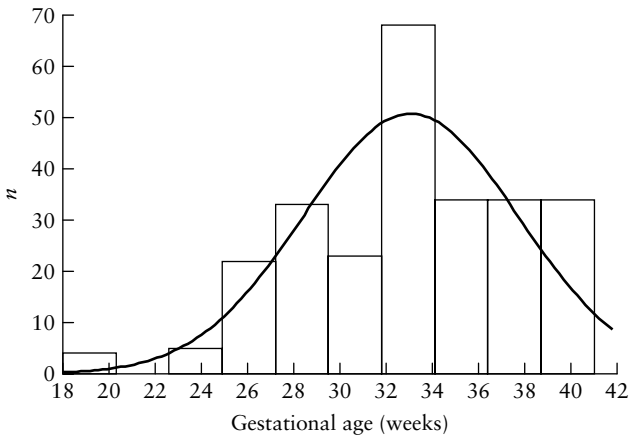

Figure 1 Histogram of gestational age at detection of fetal extrasystoles.

Figure 2 Transverse color Doppler image of the fetal liver showing hepatic veins draining into the inferior vena cava.

between the opening of the ductus venosus and the right atrium (Figure 2). The sample gate was placed over one of the branches of the hepatic veins about 5 mm from the IVC at an insonation angle of nearly 0°. All recordings were obtained during periods of fetal apnea and in the absence of fetal movements. A typical spectrum of hepatic venous blood flow velocity waveforms is illustrated in Figure 3. The type of extrasystoles, whether of atrial or ventricular origin, was noted. The women were informed of the results and an appointment was made for a detailed echocardiographic examination, which was usually performed within 2 weeks of diagnosis. A small number ($n = 12$) made an appointment for detailed echocardiographic examination without a primary venous Doppler ultrasound examination, but a venous Doppler recording was included at the time of echocardiography.

After the echocardiographic examination, the women were followed by routine antenatal surveillance, including fetal heart auscultation, by a midwife who had been instructed to readmit the woman in case of fetal brady- or tachycardia. Fetal heart rhythm and rate was recorded during labor and delivery. Newborns with extrasystoles were evaluated in the neonatal unit and electrocardiography (ECG) was performed. In the case of sustained arrhythmia for more than 3 days or, tachycardia or congenital heart malformation, the newborn was referred for evaluation at the pediatric cardiology unit.

The chi-square test was used for comparison of gender differences.

RESULTS

The median time interval between diagnosis and labor and delivery was 6 (range, 0–21) weeks. The median gestational age at labor and delivery was 40 (range,

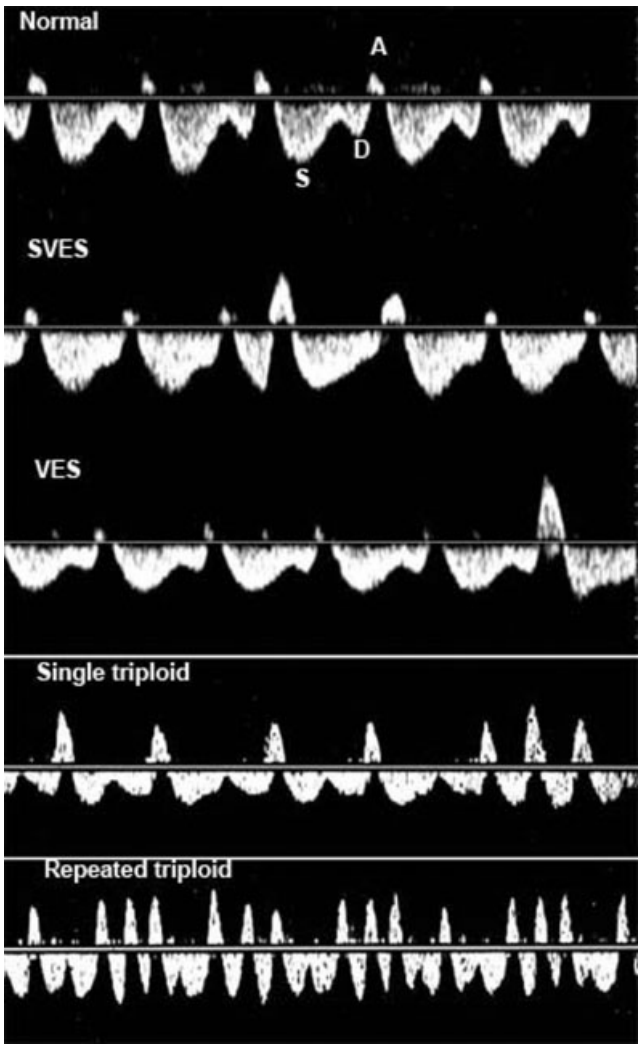

Figure 3 Spectrum of hepatic venous blood flow velocity. The upper panel shows a normal blood flow pattern, with a peak during ventricular systole (S), a peak during ventricular diastole (D) and reversal of flow velocity during atrial contraction (A) indicated. The second and third panels show the blood flow pattern during extrasystoles of atrial (SVES) and ventricular (VES) origin, respectively. The fourth panel shows the blood flow pattern in a case with triploid extra beats of atrial origin, and the fifth shows the pattern in a case with repeated triploid extra beats of atrial origin.

25–43) weeks. Umbilical artery PI was normal in all pregnancies during the initial Doppler examination.

Extrasystole was of supraventricular i.e. atrial origin (SVES) in 228 (89%) cases and of junctional or ventricular origin (VES) in 28 (11%).

In the detailed echocardiographic examination performed within 2 weeks of the venous Doppler examination, SVES had persisted in 128 (56.1%) and VES had persisted in 19 (67.9%). At assessment during labor and delivery, SVES was still present in 28 (12.3%) and VES was still present in six (21.4%). Based on the numbers with extrasystoles at fetal echocardiography, the percentages with extrasystoles persisting until labor and delivery were 21.9% (atrial origin) and 31.6% (ventricular origin). Figure 4 summarizes stage of detection and persistence of SVES and VES in the study group. In one case there

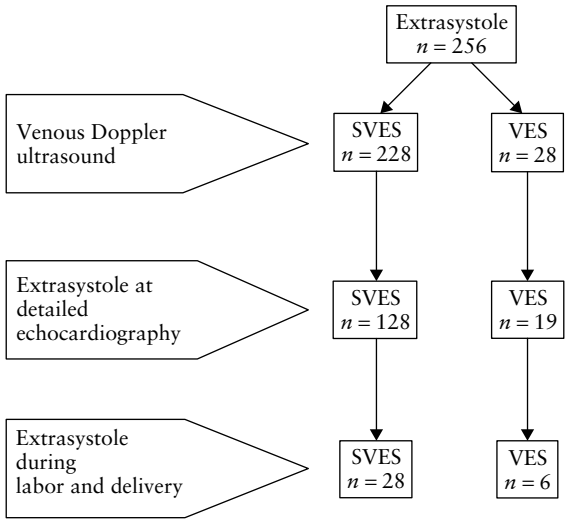

Figure 4 Flow chart showing detection and persistence of extrasystole in 256 fetuses referred due to premature fetal heart contractions. SVES, supraventricular (i.e. atrial) extrasystole; VES, ventricular extrasystole.

were periods of bigemini and in one there was a triploid extrasystolic pattern of atrial origin (Figure 3); neither of these cases developed tachycardia. However, two cases of SVES developed tachycardia, one during pregnancy (which became atrial flutter and was successfully treated by digoxin) and the other in the neonatal period.

In 31 of the 34 fetuses with extrasystoles at delivery, this disappeared immediately after birth or during the first 3 days postnatally. Five newborns were referred for pediatric cardiology evaluation. Two were followed due to persisting arrhythmias that lasted for 2 weeks and one developed supraventricular tachycardia that was treated for 2 months; all three were initially diagnosed with atrial extrasystoles. The other two cases were referred for cardiology evaluation due to congenital heart malformations (2/256 = 0.78%), one with a small muscular ventricular septal defect and the other with an atrioventricular septal defect and trisomy 21.

Gender was not significantly different at detection but, in boys, extrasystoles persisted significantly more often until labor and delivery ($P < 0.0001$). Of the 28 cases with extra heart beats of atrial origin that persisted until birth, 23 (82%) were boys, while of the six with extrasystoles of ventricular origin at birth, all were boys.

DISCUSSION

Venous Doppler blood velocity recordings can provide information indirectly on fetal central venous pressure and cardiac conduction properties. Our results suggest that this method can distinguish between electrophysiological events of atrial and ventricular origin. The majority (89.1%) of irregular beats discovered during prenatal appointments were of atrial origin and most of the cases had an uneventful course of pregnancy, labor and delivery. Only 12.3% of these persisted during labor and delivery, and most disappeared within 3 days after

delivery. Extrasystoles of ventricular origin were less common, but a greater proportion (21.4%) of them persisted throughout pregnancy compared with those of atrial origin. Only two of the 256 (0.78%) newborns had congenital heart malformation, the same frequency as that found in the general population. Furthermore, only two developed tachycardia, one during pregnancy and the other in the neonatal period. These findings strongly support the assumption that extrasystolic activity is a benign phenomenon in the immature fetal heart.

Ectopic premature contractions are usually idiopathic, but hypothetical explanations have been proposed. The most commonly attributed causes of premature extrasystoles are maternal ingestion of stimulants including caffeine[10], maternal thyroid disease, fetal or maternal catecholamine secretion, and intrinsic fetal cardiac abnormality[11]. A fetal atrial septal aneurysm or an abnormal redundancy of the flap of the foramen ovale might bulge into the left atrium, irritate and trigger electric activity in the left atrial wall[12]. An aneurysm of the foramen ovale might also cause a form of premature obstruction of right-to-left shunting during fetal life that could cause atrial arrhythmia.

M-mode ultrasound imaging of movements of the atrial and ventricular walls over time has been used for many years to trace mechanical signs of electrical conduction within the heart. During normal conduction, movement of the atrial followed by the ventricular wall can be traced as a sign of electrical depolarization[13]. However, tissue motion can be difficult to trace with precision due to fetal lie in combination with poor image quality, particularly when the atrium is dilated, thus reducing the efficacy of this method.

Another frequently used method for evaluation of fetal arrhythmia involves placing the Doppler sample volume below the mitral valve (inflow) and aortic outflow tract (outflow). The recording of in- and outflow in the left ventricle provides information on the hemodynamic consequences of electrical activity within the heart. Although this method is dependent on both heart rate and angle of insonation[14], Doppler has been shown to better reflect fetal heart electrical activity than does M-mode tracing, in both human and lamb fetuses in a laboratory setting[14,15]. However, comparison of the inflow/outflow method with recording the blood flow in the superior vena cava (SVC) and ascending aorta simultaneously (SVC/Ao method) has shown the latter to be superior, especially because it is less dependent on heart rate when the heart rate is elevated[16]. Furthermore, the inflow/outflow technique does not provide information on atrial activity during ventricular systole.

ECG has also been performed in fetal arrhythmia by means of electrodes placed on the maternal abdomen. However, the method is unsuccessful in 17% of recordings, which makes its use questionable with the present ECG technique[17]. Separating the P- and the T-waves can be difficult because of the low signal-to-noise ratio. Tracings might also be disturbed by muscular noise from the maternal abdomen or other maternal tissue activity.

The Doppler recording of hepatic venous blood flow patterns used in this study is easy to perform and has the advantage that minimal training is required to obtain traces at an insonation angle of nearly 0°. The hepatic veins are easily located in the transverse section of the fetal trunk between the ductus venosus and the right atrium. There are usually five vessels, entering the IVC (Figure 2) from the four liver lobes. Occasionally, the vessels enter the right atrium directly.

Hepatic venous Doppler reflects cardiac function and conduction properties. IVC and SVC might have been assessed instead of the hepatic veins, but recording blood velocities in these veins is technically more difficult due to the angle of insonation. The recording of blood flows in an artery and vein simultaneously has been described for the SVC and ascending aorta[16] and might be useful in diagnosing a delay in electrical transmission over the atrioventricular node. Other possible combinations of artery and vein simultaneous recording might be the renal artery and vein, or the pulmonary artery and vein. However, reversal of flow during atrial contraction might be hidden within the arterial diastolic flow spectrum and thus difficult to interpret.

The frequency of atrial and ventricular extrasystoles in our study was similar to that of previous publications. Reed *et al.*[3] reported premature atrial contractions in 76 (94%) and premature ventricular contractions in five cases. Lingman *et al.*[18] reported premature contractions of atrial origin in 94 (87%) cases and of venous origin in 14 using combined Doppler and abdominal fetal ECG.

We found that 37% of extrasystoles disappeared between initial diagnosis and fetal echocardiography performed up to 2 weeks later. Kleinman and Nehgme[19] reported that in 50% of their cases, the arrhythmia had disappeared by the time of echocardiography. Copel *et al.*[20] reported 55% of their cases to have normal rhythm during outpatient attendance for echocardiography. This divergence in results might be due to differences in time delay between detection and echocardiography.

The vast majority of fetuses with atrial or ventricular extrasystoles have an uneventful pre- and postnatal outcome in contrast to fetuses with tachy- and brady-arrhythmias, which may be of more hemodynamic significance[4,21]. Less than 1–5% of fetuses develop tachycardia, the risk apparently being highest in fetuses with multiple blocked atrial ectopic beats[4,20,22–24]. Premature ventricular contractions potentially lead to ventricular tachycardia. Fetal ventricular tachycardia is, however, diagnosed very infrequently, which might be due to these cases instead being diagnosed as intrauterine fetal deaths. None of the cases with extrasystoles of ventricular origin developed tachycardia in our study; however, two (0.78%) cases with extrasystoles of atrial origin developed tachycardia. Neither of these presented with atrial bigemini or triploid blood flow pattern during Doppler evaluation.

The lack of follow-up in the majority of cases is a limitation of this study. Only those with extrasystoles at birth were examined by electrocardiography. Ludwig *et al.*[21] achieved up to 5 years of follow-up in nearly half of their cases with extrasystoles. Their results were excellent, suggesting a good prognosis, without arrhythmia, during childhood.

The frequency of congenital heart malformations in our study was 0.78%, which is the same as that in the general population, and is in agreement with the findings of Copel *et al.*[20] and Vergani *et al.*[24]. The need for a full echocardiographic examination in cases of fetal extrasystoles might therefore be questioned. However, even though arrhythmia is usually benign with limited negative circulatory effects, parents and their physicians are troubled by the potential risk of complex arrhythmia and structural anomaly. A full fetal echocardiographic examination is therefore warranted if possible, especially in cases of multiple ectopic beats or runs of them, or in fetuses with sustained tachycardia or bradycardia. Consultation to inform the concerned parents is needed and is best provided by experts in perinatal echocardiographic evaluation. If this is not possible, reassuring information can be given and the pregnancy can be followed weekly by auscultation using a Doppler listening device in an antenatal maternity clinic. In cases of brady- or tachycardia, the woman should be readmitted for further evaluation and treatment.

In conclusion, our results suggest that hepatic venous Doppler can differentiate between SVES and VES. Despite being the more uncommon of the two, VES persists throughout pregnancy more often. Our results strongly support the suggestion that extrasystoles are a benign finding, with very few cases developing tachycardia or having a coexisting congenital heart malformation.

ACKNOWLEDGMENTS

This study was supported by Lund University's Faculty of Medicine and by research funds from the University Hospital in Malmö and Region Skåne. The ultrasonographers Lena Berg, Maria Nilsson and Pia Soikkeli are acknowledged for performing the Doppler recordings.

REFERENCES

1. Shenker L. Fetal cardiac arrhythmias. *Obstet Gynecol Surv* 1979; **34**: 561–572.
2. Strasburger JF. Fetal arrhythmias. *Prog Pediatr Cardiol* 2000; **11**: 1–17.
3. Reed KL, Sahn DJ, Marz GR, Anderson CF, Shenker L. Cardiac Doppler flows during fetal arrhythmias: physiologic consequences. *Obstet Gynecol* 1987; **70**: 1–6.
4. Simpson JM, Yates RW, Sharland GK. Irregular heart rate in the fetus – not always benign. *Cardiol Young* 1996; **6**: 28–31.
5. Włoch A, Włoch S, Sikora J, Bakon I, Rokicki W. Analysis of cases with fetal extrasystole coexisting with cardiac and extracardiac pathology. *Ginekologia Polska* 2003; **74**: 456–462.
6. Robida A. Fetal arrhythmias. *Heart Views* 2000; **1**: 358–364.
7. Gudmundsson S. Importance of venous flow assessment for clinical decision-making. *Eur J Obstet Gynecol Reprod Biol* 1999; **84**: 173–178.
8. Gosling RG, Dunbar G, King DH, Newman DL, Side CD, Woodcock JP, FitzGerald DE, Keates JS, MacMillan D. The quantitative analysis of occlusive peripheral arterial disease by a non-intrusive ultrasonic technique. *Angiology* 1971; **22**: 52–55.
9. Gudmundsson S, Marsal K. Umbilical and uteroplacental blood flow velocity waveforms in normal pregnancy – a cross-sectional study. *Acta Obstet Gynecol Scand* 1988; **67**: 347–354.
10. Oei SG, Vosters RPL, van der Hagen NLJ. Fetal arrhythmia caused by excessive intake of caffeine by pregnant women. *BMJ* 1989; **298**: 568.
11. McCurdy CM, Reed KL. Fetal arrhythmias. In *Doppler Ultrasound in Obstetrics and Gynecology*, Copel and Reed (eds). Raven Press: New York, 1995; 260.
12. Rice MJ, McDonald RW, Reller MD. Fetal atrial septal aneurysm: a cause of fetal atrial arrhythmias. *J Am Coll Cardiol* 1988; **12**: 1292–1297.
13. Allan LD, Crawford DC, Anderson RH, Tynan M. Evaluation and treatment of fetal arrhythmias. *Clin Cardiol* 1984; **7**: 467–473.
14. Fouron JC, Proulx F, Miro J, Gosselin J. Doppler and M-mode ultrasonography to time fetal atrial and ventricular contractions. *Obstet Gynecol* 2000; **96**: 732–736.
15. Dancea A, Fouron JC, Miro J, Skoll A, Lessard M. Correlation between electrocardiographic and ultrasonographic time-interval measurements in fetal lamb heart. *Pediatr Res* 2000; **47**: 324–328.
16. Andelfinger G, Fouron JC, Sonesson SE, Proulz F. Reference values for time intervals between atrial and ventricular contractions of the fetal heart measured by two Doppler techniques. *Am J Cardiol* 2001; **88**: 1433–1436.
17. Taylor MJ, Smith MJ, Thomas M, Cheng F, Oseku-Afful S, Wee LY, Fisk NM, Gardiner HM. Non-invasive fetal electrocardiography in singleton and multiple pregnancies. *Br J Obstet Gynaecol* 2003; **110**: 668–678.
18. Lingman G, Lundstrom NR, Marsal K. Clinical outcome and circulatory effects of fetal cardiac arrhythmia. *Acta Paediatr Scand* 1986; **329**: 120–126.
19. Kleinman CS, Nehgme RA. Cardiac arrhythmias in the human fetus. *Pediatr Cardiol* 2004; **25**: 234–251.
20. Copel JA, Liang RI, Demasio K, Ozeren S, Kleinman CS. The clinical significance of the irregular fetal heart rhythm. *Am J Obstet Gynecol* 2000; **182**: 813–817.
21. Ludwig AK, Chase K, Axt-Fliedner R, Gembruch U, Didrich K, Krapp M. Follow-up of children with prenatal diagnosis of supraventricular extrasystole. *Ultraschall Med* 2009; **30**: 564–570.
22. Kleinman CS, Copel JA, Weinstein EM, Santulli TV, Hobbins JC. In utero diagnosis and treatment of fetal supraventricular tachycardia. *Semin Perinatol* 1985; **9**: 113–129.
23. Cuneo BF, Strasburger JF, Wakai RT, Ovadia M. Conduction system disease in fetuses evaluated for irregular cardiac rhythm. *Fetal Diagn Ther* 2006; **21**: 307–313.
24. Vergani P, Mariani E, Ciriello E, Locatelli A, Strobelt N, Galli M, Ghidini A. Fetal arrhythmias: natural history and management. *Ultrasound Med Biol* 2005; **31**: 1–6.

