

# A Review of Findings in Fetal Cardiac Section Drawings

## Part 3: The 3-Vessel-Trachea View and Variants

*Philippe Jeanty, MD, PhD, Rabih Chaoui, MD,  
Irina Tihonenko, MD, Frantisek Grochal, MD*

**Objective.** The goal of this presentation is to review some of the common and rare fetal heart abnormalities and to provide an easy approach to these findings with the schematic drawings. **Methods.** Over the past 10 years, we collected cases in which the common views of the heart were abnormal and the differential diagnoses that existed for each. This presentation shows the normal sonographic sections and then variations of these sections and the associated anomalies. We used illustrative drawings to present these findings, enabling us to point out the main sonographic features of abnormalities of the heart. **Results.** This work reviews 21 fetal heart abnormalities in schematic drawings. **Conclusions.** This short review highlights several of the anomalies that can be recognized on the common sonographic views. The drawings tend to simplify the findings but should serve as a basis for those doing fetal echocardiography when they encounter an unusual finding. **Key words:** drawings; fetal echocardiography; prenatal sonography.

**I**n this third part of our 3-part series, we review the prenatal sonographic findings of some cardiac anomalies at the level of the 3-vessel-trachea view. Many of the cardiac anomalies result in modifications of the anatomy, position, or direction of flow at the level of the structures in the upper thoracic region. The purpose of this presentation is to provide schematic drawings of these findings to serve as an easy reference for those anomalies.

### Materials and Methods

We have summarized the typical findings of some cardiac anomalies collected over the past 10 years.

The colors used in the drawings are conventional medical artist colors, with arteries in red and veins in purple or blue. The colors do not represent flow directions, as in color Doppler sonography, for instance, and they do not correlate with fetal blood oxygenation. A few drawings (cases 10–17) use colors that represent color Doppler images, and those drawings are clearly identified. The drawings are presented with the fetus presenting in the cephalic dorsal position (Figure 1). Although this does not represent the conventional position used in computed tomography and magnetic resonance imaging, it will be more familiar to those who do prenatal sonographic examinations.

*Received July 22, 2007, from Inner Vision Women's Ultrasound, Nashville, Tennessee USA (P.J.); Center for Prenatal Diagnosis and Human Genetics, Berlin, Germany (R.C.); Ultrasound Department, First City Hospital, Minsk, Belarus (I.T.); and Gynekologicko Pôrodnické Oddelenie, Ústredná Vojenská Nemocnica SNP Ružomberok, Ružomberok, Slovak Republic (F.G.). Manuscript accepted for publication July 24, 2007.*

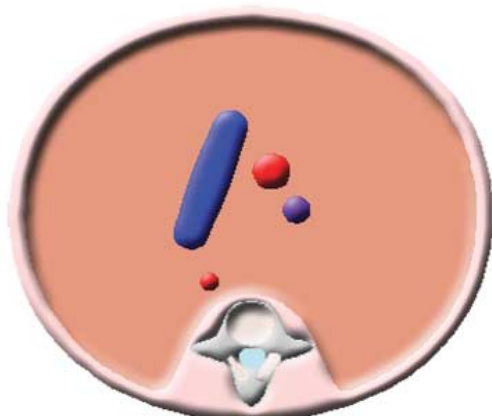
*Address correspondence to Philippe Jeanty, MD, PhD, Inner Vision Women's Ultrasound, 2201 Murphy Ave, Suite 203, Nashville, TN 37203 USA.  
E-mail: pjeanty@gmail.com*



**Figure 1.** Fetus in the cephalic dorsal position. The subsequent drawings are depicted with the fetus in this position.

In the following descriptions and drawings, we review some anomalies at the level of the 3-vessel-trachea view. Figure 2 represents a normal 3-vessel-trachea view to serve as a reference image for comparison with the subsequent drawings representing anomalies. The drawing shows the pulmonary artery, the aorta, and the superior vena cava. Some of the following drawings also show the trachea and esophagus, which we have represented here in Figure 3.

**Figure 2.** Normal 3-vessel-trachea view. This drawing serves as a reference image for comparison with the subsequent drawings representing anomalies. The pulmonary artery is depicted as a straight structure in blue; the ascending aorta is the round red structure next to the pulmonary artery; the superior vena cava is the round purple structure next to the ascending aorta; and the descending aorta is the round red structure located posteriorly close to the spine.



## Results

### Case 1

In this case, the 3-vessel view shows a thin pulmonary artery and a large aorta (Figure 4). This indicates an increase in flow in the left side with a concomitant decrease in the right. This could be present in tetralogy of Fallot, pulmonary atresia, pulmonary atresia with a ventricular septal defect (VSD), a double-outlet right ventricle, and a truncus arteriosus.<sup>1,2</sup>

### Case 2

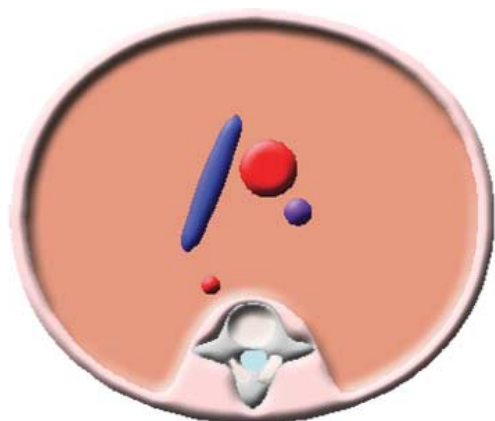
In this case, the 3-vessel view shows the reverse of case 1: a thin aorta and a large pulmonary artery (Figure 5). These findings can represent aortic atresia/stenosis, coarctation of the aorta, and a double-outlet right ventricle. The double-outlet right ventricle is in the previous category too: it depends on whether the aorta or the pulmonary artery shows an obstruction.<sup>1</sup> Another rare condition with a huge dilated pulmonary artery is absent pulmonary valve syndrome<sup>3,4</sup> (see case 1).

### Case 3

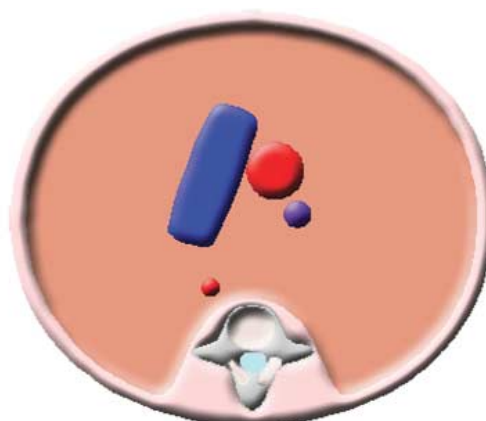
This case is a tricky one (Figure 6). If both great vessels are enlarged, it cannot be that one is enlarged at the expense of the other. Therefore, a different explanation is required. The only way to get increased flow in both vessels is to have incompetent valves in both vessels. Thus, the increase in flow is due to regurgitation of the incompetent aortic and pulmonary valves.

**Figure 3.** Trachea and esophagus used in some of the following images.





**Figure 4.** Case 1. Three-vessel view showing a thin pulmonary artery (blue) and an enlarged aorta (red).



**Figure 6.** Case 3. Three-vessel view showing enlargement of both the pulmonary artery (blue) and aorta (red).

Occasionally, with atrioventricular blocks, the vessels may also be dilated, as in this case.

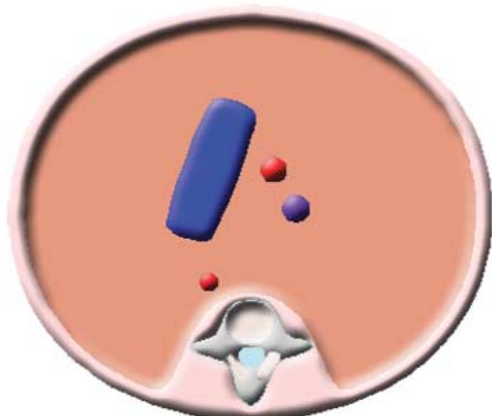
**Case 4**

In this case, the little red “buglike” structure shown on the drawing is a double aortic arch (Figure 7). The appearance is due to its division into right and left aortic arches, each with its own common carotid and subclavian arteries.<sup>5-7</sup> This diagnosis is almost impossible in sagittal and parasagittal views because they would appear as normal arches (though with only 2 brachiocephalic vessels). Note that the trachea and esophagus are located in the division of the 2 branches. This would be responsible for dysphagia and stridor after birth.

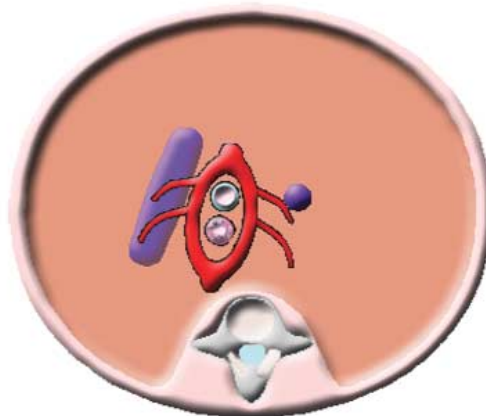
**Case 5**

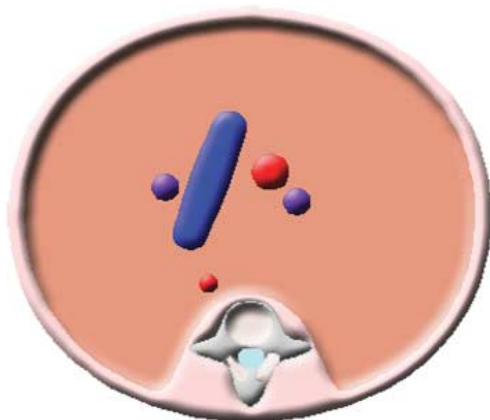
In this case, the abnormal finding is a vein on the left side of the pulmonary artery (Figure 8). Although the finding is easy to recognize on this view, it is commonly missed because it is not sought. This is the classic finding of a persistent left superior vena cava.<sup>7</sup> Lower at the level of the 4-chamber view, we could see a vessel in the atrioventricular groove. The persistent left superior vena cava will drain either in the back of the left atrium or in the coronary sinus.<sup>8-13</sup> The distension of the coronary sinus will appear as a transverse line (roughly parallel to the atrioventricular valve) in the lower aspect of the left atrium.

**Figure 5.** Case 2. Three-vessel view showing an enlarged pulmonary artery (blue) and a thin aorta (red).




**Figure 7.** Case 4. Three-vessel-trachea view showing a double aortic arch (red) surrounding the trachea (anteriorly) and esophagus (posteriorly).





**Figure 8.** Case 5. Three-vessel-trachea view showing a supernumerary vascular structure (purple) on the left of the pulmonary artery (blue), which represents a persistent left superior vena cava.



**Figure 10.** Case 7. Three-vessel-trachea view showing both great vessels in parallel (aorta in red, pulmonary artery in blue, and superior vena cava in purple). In real life, they are more or less parallel but rarely on the same plane.

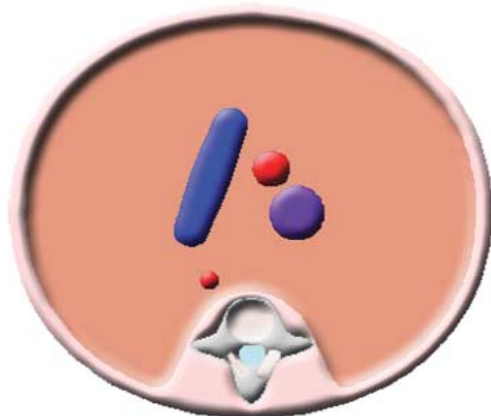
**Case 6**

This case represents an enlarged superior vena cava (Figure 9). This is the final level at which to recognize an inferior vena cava interruption with azygos or hemizygos continuation. Another possibility is an anomalous pulmonary venous return with a supracardiac connection or increased circulation of the brain, as found in a vein of Galen aneurysm.

**Case 7**

In this case, the great vessels arise in parallel, thus representing transposition of the great arteries (Figure 10). The drawing is a little simplified because the vessels are rarely at the same level but tend to curl under each other, usually with the transposed aorta more cephalad than the pulmonary artery.

**Figure 9.** Case 6. Three-vessel-trachea view showing an enlarged superior vena cava (purple).



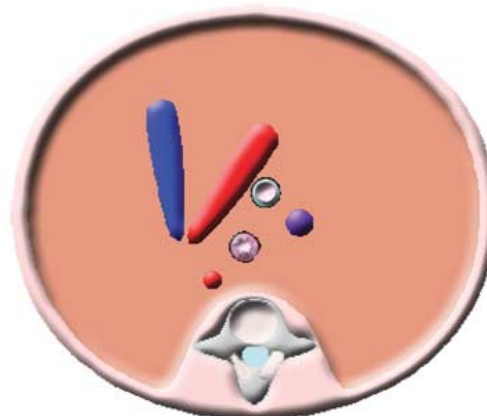
**Convergence of the Great Vessels**

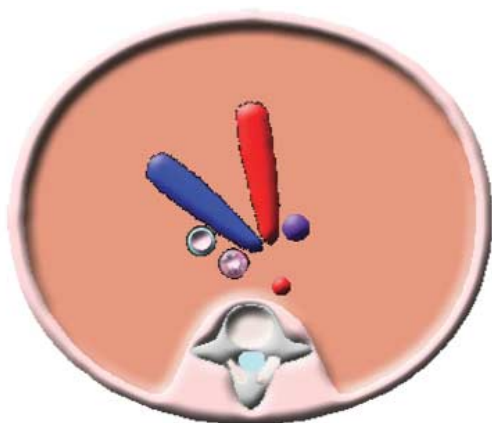
The next 2 images are at a slightly different level than the regular 3-vessel view. This is the level at which the confluence of the aorta and pulmonary artery can be observed. A normal section at this level is depicted in Figure 11.

**Case 8**

In this case, the “V-shaped” confluence of the aorta and ductus points to the right of the trachea (Figure 12). This is a sign of a right-sided aortic arch.<sup>14</sup> Right-sided refers to the position of the arch compared with the trachea, not to the position of the descending aorta.

**Figure 11.** Normal confluence of the ductal and aortic arches. The descending aorta, which is on a lower plane, is “shown by transparency.” It is represented to indicate the position of the descending aorta in lower images. Again, note the positions of the trachea and esophagus (using the same symbols as in Figure 3).





**Figure 12.** Case 8. Upper transverse thoracic view showing a V-shaped confluence of the aorta (red) and ductus (blue). The trachea and esophagus are located to the left of the ductus.

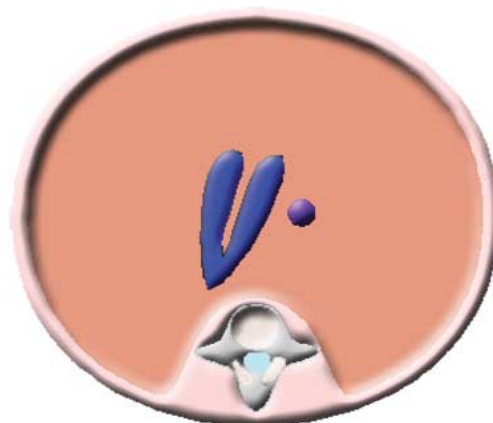
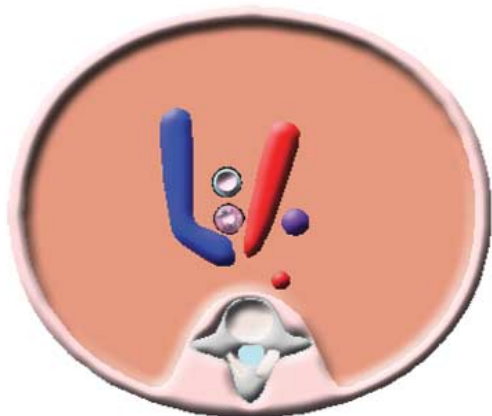
### Case 9

In this case, the “U-shaped” confluence of the aorta, pulmonary artery, and ductus encircles the trachea (Figure 13). This too is a sign of a right-sided aortic arch. This is one of the “rings and slings” that will cause dysphagia and stridor in the young child.<sup>14</sup>

### Color Doppler Imaging

In the next few drawings, which are in a section similar to that in Figure 11, we represent the color Doppler information so that we can show findings in which a color Doppler signal is useful for the diagnosis. In these cases, the conventional assignment of color (blue going away from the transducer and red going toward the transducer

**Figure 13.** Case 9. Upper transverse thoracic view showing a U-shaped confluence of the aorta (red) and pulmonary artery (blue). The trachea and esophagus are located between the aorta and the ductus.



**Figure 14.** Normal 3-vessel view. The colors given to the vascular structures in the following drawings correspond to color Doppler representations. Flow in the pulmonary artery (left) and aorta (right) is directed away from the transducer toward the spine. (We presume that the transducer is placed on the top of the image.)

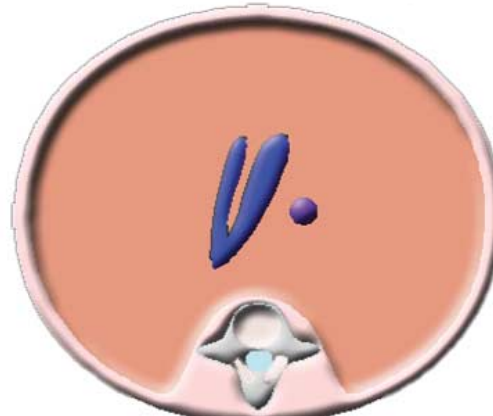
with the transducer assumed to be on top of the drawing) has been respected. The great vessels are in their expected positions.

Figure 14 represents an image that we would expect with both great vessels having about the same size and antegrade flow.

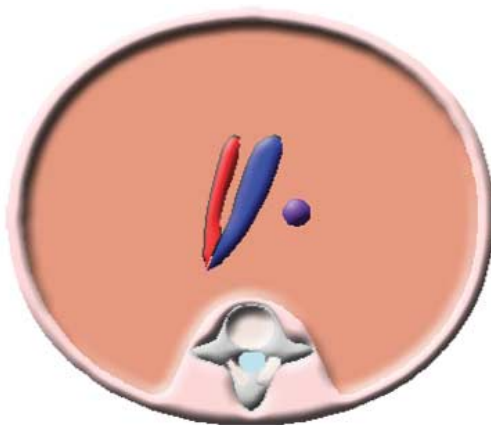
### Case 10

In this case, both vessels have antegrade flow, and the pulmonary artery is thinner than the aorta (Figure 15). This would thus suggest a right-sided restriction such as pulmonary stenosis, an Ebstein anomaly, tetralogy of Fallot, or a double-outlet right ventricle. This is similar to case 1.

**Figure 15.** Case 10. Upper transverse thoracic view. Both great vessels have antegrade flow, but the pulmonary artery (left) is thinner than the aorta (right).







**Figure 16.** Case 11. Upper transverse thoracic view. The flow within the aorta has a normal antegrade direction (blue), but the flow within the pulmonary artery has a retrograde direction (red).

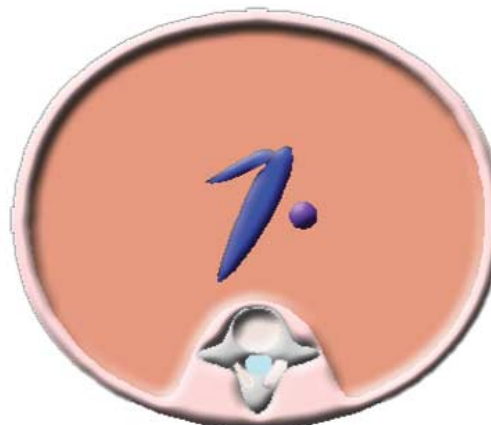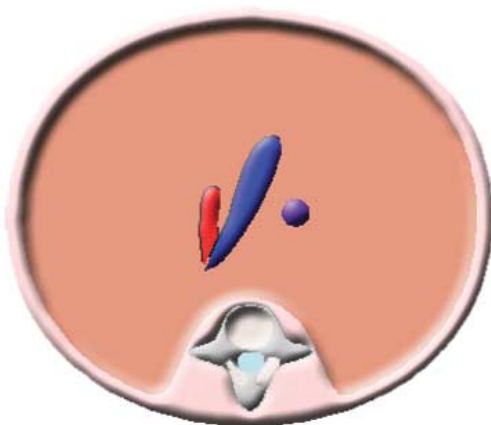
**Case 11**

In this case, color Doppler sonography shows antegrade flow in the aorta and retrograde flow in the pulmonary artery (Figure 16). This would suggest pulmonary atresia with an intact septum or with a ventricular septal defect.<sup>15</sup>

**Case 12**

The difference between this case and case 11 is that only minimal retrograde flow exists in the pulmonary artery (Figure 17). This would suggest pulmonary atresia with a ventricular septal defect, and the flow is blood going to the lungs only. The main pulmonary artery is missing and not visible.<sup>15</sup>

**Figure 17.** Case 12. Upper transverse thoracic view. The flow within the aorta has a normal antegrade direction (blue), but the minimal flow within the pulmonary artery has a retrograde direction (red).



**Figure 18.** Case 13. Upper transverse thoracic view showing a thin pulmonary artery arising from the aorta, the hallmark of a truncus arteriosus.

**Case 13**

In this case, the thin pulmonary artery arises from the aorta (Figure 18), the hallmark of a truncus arteriosus.<sup>16</sup>

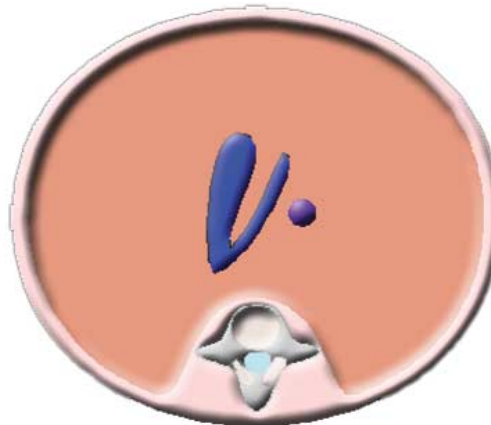
**Case 14**

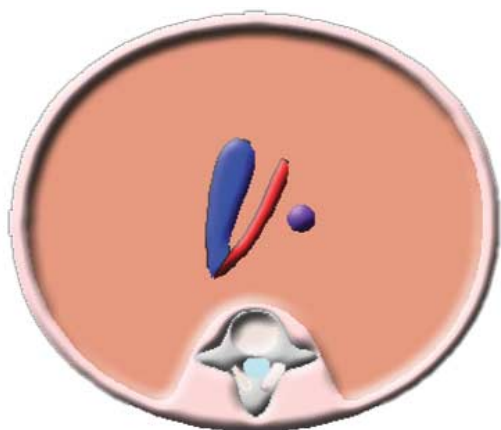
In this case, both vessels have antegrade flow, but now the pulmonary artery is larger than the aorta (Figure 19). This finding can be seen in coarctation of the aorta.<sup>16-18</sup>

**Case 15**

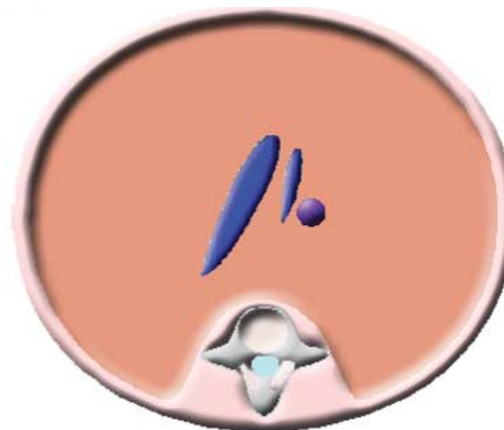
With antegrade flow in the pulmonary artery but retrograde flow in the aorta (Figure 20), we are probably dealing with hypoplastic left heart syndrome with reversed flow to the coronary arteries.<sup>18-20</sup>

**Figure 19.** Case 14. Upper transverse thoracic view. Both great vessels have normal antegrade flow, but the pulmonary artery (left) is larger than the aorta (right).





**Figure 20.** Case 15. Upper transverse thoracic view. The flow within the aorta has an abnormal retrograde direction (red), but the flow within the pulmonary artery has a normal antegrade direction (blue).



**Figure 22.** Case 17. Upper transverse thoracic view. The minimal antegrade flow within the aorta and the normal appearance and direction of the flow within the pulmonary artery are visible. This drawing represents an interrupted aortic arch.

**Case 16**

A partially visible aortic arch (Figure 21) should suggest an interrupted aortic arch. Because the pulmonary artery is arising from the arch, this is called a hemitruncus.<sup>21,22</sup>

**Case 17**

Although this image (Figure 22) is quite similar to the previous one (Figure 21, case 16), the aorta in this case is independent from the pulmonary artery. This finding suggests a simple interruption of the aortic arch.

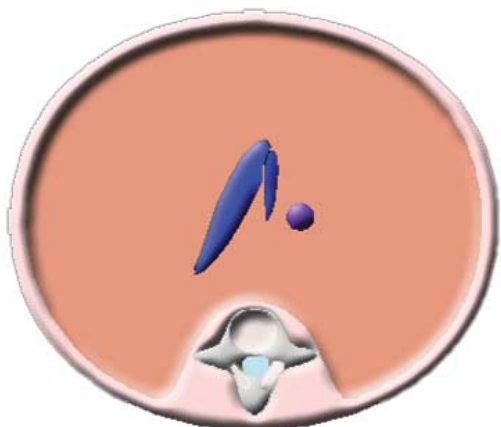
**Differential Diagnoses of Overriding Aorta**

In the next set of drawings, we review the approach to cases of an overriding aorta and concentrate on how to use the 3-vessel view to approach the differential diagnosis. Figure 23 depicts the overriding aorta in a 4-chamber view of the heart.

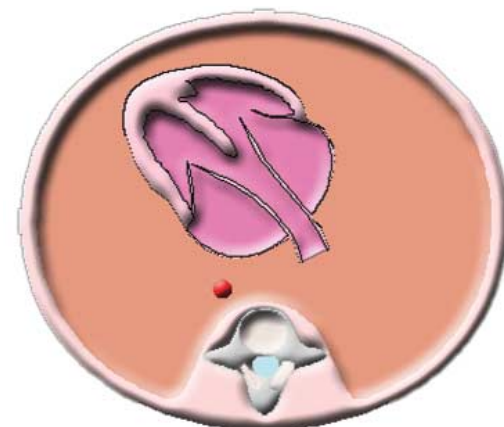
**Case 18**

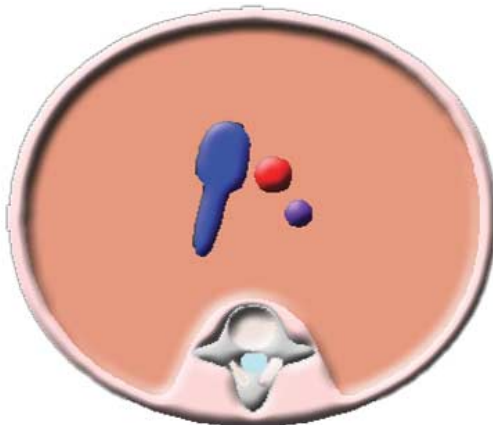
When the pulmonary artery appears normal in size (Figure 24), we are probably dealing with a malalignment ventricular septal defect<sup>23</sup> in a mild form of tetralogy of Fallot.

**Figure 21.** Case 16. Upper transverse thoracic view. The minimal antegrade flow within the aorta represents an interrupted aortic arch. The pulmonary artery has antegrade flow and arises from the aortic arch. This drawing represents a hemitruncus.

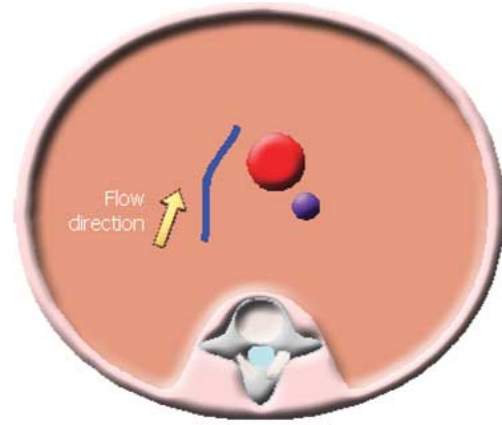


**Figure 23.** Four-chamber view of the heart showing the overriding aorta.





**Figure 24.** Case 18. Three-vessel view showing an almost normal-sized pulmonary artery (blue).



**Figure 26.** Case 20. Three-vessel view showing a thin and tortuous pulmonary artery (blue) with a reversed direction of flow.

**Case 19**

When the pulmonary artery is thin (Figure 25), then classic tetralogy of Fallot is the most likely diagnosis.

**Case 20**

When the pulmonary artery and ductus are not only thin but also tortuous (Figure 26), and the flow is reversed (ductal dependent), then the likely diagnosis is pulmonary atresia with a ventricular septal defect.<sup>24</sup>

**Case 21**

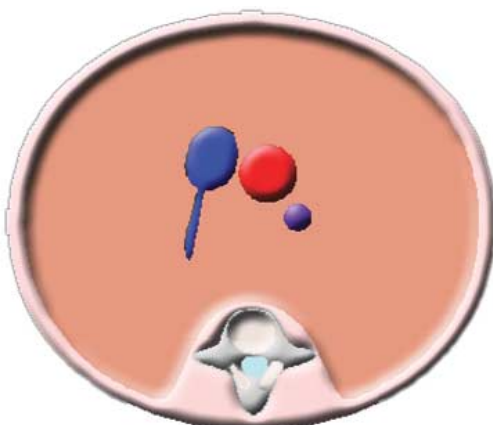
This is another unusual case but so characteristic that it is well worth mentioning. Massive dilata-

tion of the pulmonary artery (Figure 27) is due to "absent" pulmonary valve syndrome.<sup>4</sup> (Although the valve is rarely totally absent, it is usually very incompetent.)

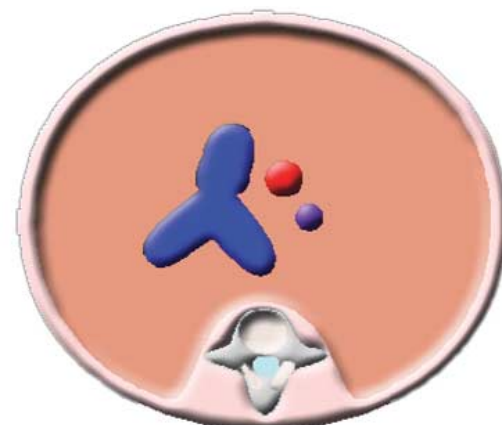
**Conclusions**

This short review highlights several of the anomalies that can be recognized on 3-vessel sonographic views and with color Doppler imaging. The drawings tend to simplify the findings, but our goal was to create simple and easily memorable patterns of some anomalies that can serve as a basis for those doing fetal echocardiography when they encounter an unusual finding.

**Figure 25.** Case 19. Three-vessel view showing a thin pulmonary artery.



**Figure 27.** Case 21. Three-vessel view showing massive dilatation of the pulmonary artery (blue).





## References

1. Yoo SJ, Lee YH, Cho KS. Abnormal three-vessel view on sonography: a clue to the diagnosis of congenital heart disease in the fetus. *AJR Am J Roentgenol* 1999; 172: 825–830.
2. Yoo SJ, Lee YH, Kim ES, et al. Tetralogy of Fallot in the fetus: findings at targeted sonography. *Ultrasound Obstet Gynecol* 1999; 14:29–37.
3. Becker R, Schmitz L, Guschmann M, Wegner RD, Stiemer B, Entezami M. Prenatal diagnosis of familial absent pulmonary valve syndrome: case report and review of the literature. *Ultrasound Obstet Gynecol* 2001; 17:263–267.
4. Volpe P, Paladini D, Marasini M, et al. Characteristics, associations and outcome of absent pulmonary valve syndrome in the fetus. *Ultrasound Obstet Gynecol* 2004; 24:623–628.
5. Paul JF, Serraf A. Images in cardiovascular medicine: truncus arteriosus and double aortic arch. *Circulation* 2002; 105:e170.
6. Chaoui R, Kalache KD, Heling KS, Tennstedt C, Bommer C, Korner H. Absent or hypoplastic thymus on ultrasound: a marker for deletion 22q11.2 in fetal cardiac defects. *Ultrasound Obstet Gynecol* 2002; 20:546–552.
7. Achiron R, Rotstein Z, Heggsh J, et al. Anomalies of the fetal aortic arch: a novel sonographic approach to in-utero diagnosis. *Ultrasound Obstet Gynecol* 2002; 20:553–557.
8. Rein AJ, Nir A, Nadjari M. The coronary sinus in the fetus. *Ultrasound Obstet Gynecol* 2000; 15:468–472.
9. Kalache KD, Romero R, Conoscenti G, et al. Prenatal diagnosis of dilated coronary sinus with persistent left superior vena cava in a fetus with trisomy 18. *Prenat Diagn* 2003; 23:108–110.
10. Chaoui R, Heling KS, Kalache KD. Caliber of the coronary sinus in fetuses with cardiac defects with and without left persistent superior vena cava and in growth-restricted fetuses with heart-sparing effect. *Prenat Diagn* 2003; 23:552–557.
11. Jouannic JM, Picone O, Martinovic J, Fermont L, Dumez Y, Bonnet D. Diminutive fetal left ventricle at mid-gestation associated with persistent left superior vena cava and coronary sinus dilatation. *Ultrasound Obstet Gynecol* 2003; 22:527–530.
12. Berg C, Knuppel M, Geipel A, et al. Prenatal diagnosis of persistent left superior vena cava and its associated congenital anomalies. *Ultrasound Obstet Gynecol* 2006; 27:274–280.
13. Pasquini L, Belmar C, Seale A, Gardiner HM. Prenatal diagnosis of absent right and persistent left superior vena cava. *Prenat Diagn* 2006; 26:700–702.
14. Zidere V, Tsapakis EG, Huggon IC, Allan LD. Right aortic arch in the fetus. *Ultrasound Obstet Gynecol* 2006; 28: 876–881.
15. Uerpaiojkit B, Charoenvidhya D, Tannirandorn Y, Chottivittayatanakorn P, Witoonpanich P, Phaosavasdi S. Prenatal diagnosis of pulmonary atresia by fetal echocardiography. *J Obstet Gynaecol Res* 1997; 23:365–368.
16. Muhler MR, Rake A, Schwabe M, et al. Truncus arteriosus communis in a midtrimester fetus: comparison of prenatal ultrasound and MRI with postmortem MRI and autopsy. *Eur Radiol* 2004; 14:2120–2124.
17. Carvalho JS. Re: fetal aortic isthmus growth and morphology in late gestation. *Ultrasound Obstet Gynecol* 2002; 20:100–101.
18. Chaoui R, Bollmann R. Fetal color Doppler echocardiography, part 2: abnormalities of the heart and great vessels. *Ultraschall Med* 1994; 15:105–111.
19. Hata K, Hata T, Manabe A, Kitao M. Hypoplastic left heart syndrome: color Doppler sonographic and magnetic resonance imaging features in utero. *Gynecol Obstet Invest* 1995; 39:70–72.
20. Chaoui R, Tennstedt C, Goldner B. Prenatal diagnosis of ventriculocoronary arterial fistula in a fetus with hypoplastic left heart syndrome and aortic atresia. *Ultrasound Obstet Gynecol* 2002; 20:75–78.
21. Marasini M, Cordone M, Zampatti C, Pongiglione G, Bertolini A, Ribaldone D. Prenatal ultrasonic detection of truncus arteriosus with interrupted aortic arch and truncal valve regurgitation. *Eur Heart J* 1987; 8:921–924.
22. Yasukochi S, Satomi G. Fetal diagnosis of common arterial trunk with interrupted aortic arch using color power Doppler angiography. *Cardiol Young* 2000; 10:54–56.
23. Paladini D, Palmieri S, Lamberti A, Teodoro A, Martinelli P, Nappi C. Characterization and natural history of ventricular septal defects in the fetus. *Ultrasound Obstet Gynecol* 2000; 16:118–122.
24. Khoshhal S, Sandor GG, Duncan WJ. Pulmonary atresia with intact ventricular septum and antenatal left ventricular failure. *Cardiol Young* 2004; 14:335–337.